



PATIENT

Tigger Deloria

SPECIES

Feline

BREED

DSH

SEX

Male Neutered

AGE

4 years

WEIGHT

14.2lbs

INTERPRETED BY

Maggie Machen
Lamy, DVM
DACVIM (Cardiology)

IMAGING

PERFORMED BY

Pamela Harrigan,
RDCS

HOSPITAL NAME

Mass Veterinary
Services

REFERRING VET

Dr. Masloski

INVOICE

22757

DATE

2/23/22

PRESENTING CLINICAL SIGNS

History: Tigger's brother was treated for an ATE +/- PTE in November. He is one of a litter of 7, three of whom have died. His biological mother is reported to have had heart disease. Presently doing well with no problems noted. Eating well with normal activity. On auscultation: NSR, no murmurs noted, PSS, lung fields clear, compressible thorax. BP: 150mmHg x 5. No medications. *No sedation for study.

ECHOCARDIOGRAM FINDINGS

2D, m-mode, color flow and Doppler imaging is available.

Left ventricle: The LV diameter is normal with adequate myocardial function. The LV wall thicknesses are normal. There is a diffusely hyperechoic endocardium consistent with mild fibrosis. The endocardium appears mildly remodeled. The papillary muscles are mildly remodeled and hyperechoic.

Left atrium: The left atrium is mildly increased in size. No obvious spontaneous contrast or thrombi seen.

Mitral valve: The mitral valve is normal in structure and mobility with no mitral regurgitation. No obvious systolic anterior motion is seen.

Aortic valve/aorta: The aortic valve is normal in morphology and mobility. Normal aortic outflow velocity; laminar flow. No aortic insufficiency.

Right ventricle: Normal right ventricular diameter and morphology indicating no overt evidence of pulmonary arterial hypertension.

Right atrium: The right atrium is normal in dimension.

Tricuspid valve: The tricuspid valve appears normal with no tricuspid regurgitation.

Pulmonic valve/pulmonary artery: The pulmonic valve is normal in morphology and mobility. No pulmonic insufficiency. Normal RVOT velocity; laminar flow.

Pericardium/other: No pericardial or pleural effusion noted. No obvious cardiac masses.

Heart rhythm: ECG reveals a sinus rhythm with an average HR of 200bpm.

2-Dimensional Measurements

Ao diam (cm)	1.1
LA diam (cm)	1.5
LA:Ao (Swe)	1.5
IVS thickness (cm)	0.47
LVID diastole (cm)	1.44
PW thickness (cm)	0.51
LVID systole (cm)	0.50
FS (%)	64

Doppler Measurements

PV Vmax (m/s)	0.9
AoV Vmax (m/s)	1.2
MR Vmax (m/s)	NA
TR Vmax (m/s)	NA
TR PG (mmHg)	NA

INTERPRETATION OF THE FINDINGS

Overtly normal cardiac structure and function. There is mild remodeling and fibrosis of the left ventricular wall, which most likely represents a normal variant. No evidence of hypertrophic disease. The only concerning finding is the LA measures mildly enlarged, which may be indicative of early restrictive or unclassified disease or again may be a normal variant. No matter the categorical diagnosis, a cat with any degree of LA enlargement should be followed up closely, as there is evidence of increasing LA pressure which may progress in the future. Serial echocardiography will be necessary to determine progression. No additional issues are identified.



PATIENT

Tigger Deloria

SPECIES

Feline

BREED

DSH

SEX

Male Neutered

AGE

4 years

WEIGHT

14.2lbs

INTERPRETED BY

Maggie Machen Lamy, DVM
DACVIM (Cardiology)

IMAGING PERFORMED BY

Pamela Harrigan, RDCS

HOSPITAL NAME

Mass Veterinary Services

REFERRING VET

Dr. Masloski

INVOICE

22757

DATE

2/23/22

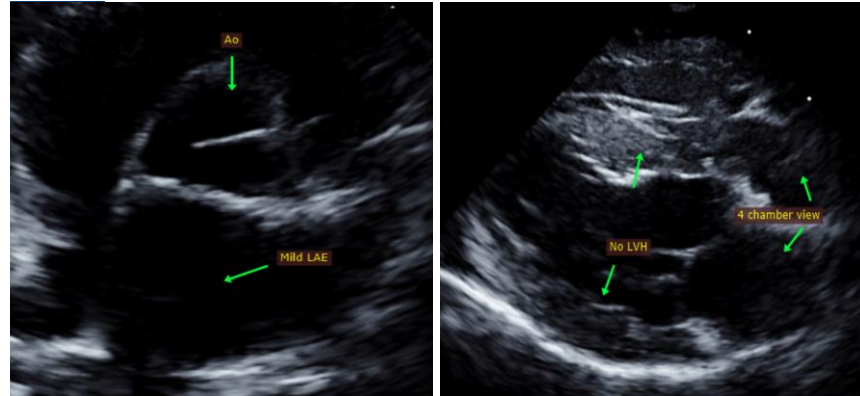
RECOMMENDATIONS

- Given these findings, no medications are indicated.
- The risk for general anesthesia is low, however heart rate stimulating drugs such as atropine, glycopyrrolate, etc. should be avoided unless medically necessary. With mild LA dilation there may be an elevated risk for fluid overload in this patient and judicious IV fluid use is recommended.
- Monitor for any clinical evidence of cardiac compromise, including respiratory changes and/or signs of a blood clot event (paralysis, neurologic changes, etc).

PLAN

- Recommend recheck echocardiogram in 6-12 months to screen for progression.

IMAGES



The information and recommendations provided are based on the images presented by the referring veterinarian. No evaluation can be communicated regarding pathology that was not visible in the image/video clips provided.

Thank you for this referral. This report was generated using transcription software, and minor dictation errors may be present. If the clinical or image interpretation does not parallel your findings or if I can be of any further assistance, please contact me.

Maggie Machen Lamy, DVM
Diplomate of the American College of Veterinary Internal Medicine (Cardiology)
info@sonopath.com

Echocardiogram performed by:

Pamela Harrigan, RDCS
Pet Animal Ultrasound Service (4paus.com)